

ELECTROCARDIOGRAMS AND IMAGING STUDIES

SAMPLE CASES

This Sample Cases document contains three examples of cases you will see on the Electrocardiogram (ECG) and Imaging Studies component of the Cardiovascular Disease Certification Examination. The first is an ECG case, the second is an echocardiogram case, and the third is a coronary angiogram case. Correct answers for these sample cases are discussed on page 15 - 18.

An answer option list is provided for each case, representing a comprehensive list of findings that may be obtained on an ECG, an echocardiogram, or an angiogram. Each case has a patient description at the top of the answer option list and a "Figure/Media" button to access the image(s).

You should interpret the cases as you would in everyday practice. It is suggested that you first read the patient description and interpret the image(s), identifying any abnormalities. You should then find and select the appropriate answer option(s) that correspond to your findings.

As in real life, a clinical diagnosis frequently is not possible without additional clinical data. You should identify only those findings that are definite and that you consider important. The examination is not an exercise in identifying minutiae or clinically unimportant details; rather, it is an exercise in identifying those findings that are clearly apparent and significant to patient management.

Correct answers for some cases will include options from several sections; within a section, it may be appropriate to select more than one option. However, a selection of options from all sections is not required for each case. Your score for each case depends on selection of the option(s) that correctly describe(s) the findings. A correct selection may be invalidated by 1) selecting options that could lead to an incorrect interpretation, or 2) selecting mutually exclusive options that could not coexist with the correct findings.

Note: This document contains only still-frame images; however, the actual Imaging Studies component of the exam and the Exam Tutorial contain moving images. In addition, the answer options in this document are not selectable. The tutorial available will have full functionality that will be similar to what you will see on the actual exam.

Copyright and Examination Non-Disclosure Policy

All ABIM materials are protected by the federal Copyright Act, 17 U.S.C. § 101, et seq. Access to all such materials, as further detailed below, is strictly conditioned upon agreement to abide by ABIM's rights under the Copyright Act and to maintain examination confidentiality.

ABIM examinations are confidential, in addition to being protected by federal copyright and trade secret laws. Candidates and diplomates who undertake examinations agree that they will not copy, reproduce, adapt, disclose, or transmit examinations, in whole or in part, before or after taking an examination, by any means now known or hereafter invented. They further agree that they will not reconstruct examination content from memory, by dictation, or by any other means or otherwise discuss examination content with others. Candidates and diplomates further acknowledge that disclosure or any other use of ABIM examination content constitutes professional misconduct and may expose them to criminal as well as civil liability, and may also result in ABIM's imposition of penalties against them, including but not limited to, invalidation of examination results, exclusion from future examinations, suspension, revocation of certification and other sanctions.

With respect to ABIM's Maintenance of Certification (MOC) products, including its Medical Knowledge Modules and ABIM PIMs Practice Improvement Modules®, candidates agree that they will not copy, reproduce or make any adaptations of such materials in any manner; and will not assist someone else in the infringement or misuse of these or any other ABIM-copyrighted works.

CARDIOVASCULAR DISEASE CERTIFICATION EXAMINATION

ELECTROCARDIOGRAMS

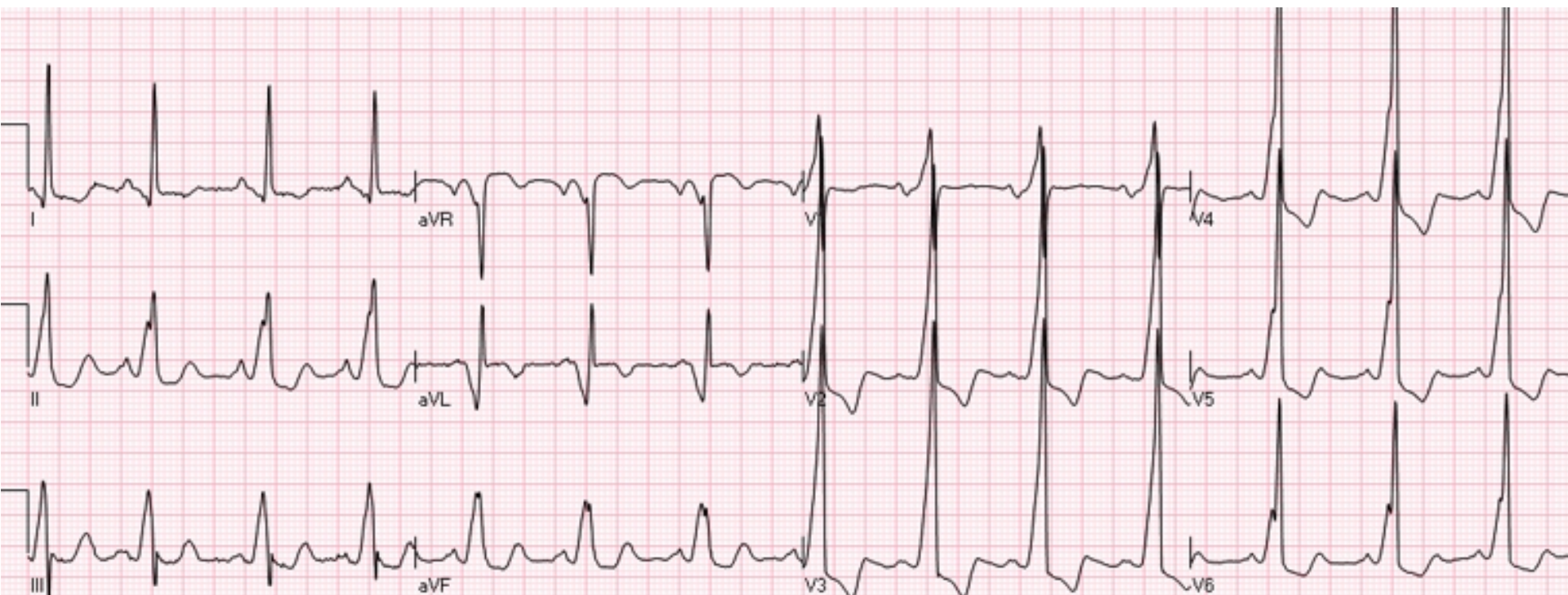
The Electrocardiogram (ECG) section of the Cardiovascular Disease Certification examination is designed to test your ability to interpret electrocardiograms.

Pages 3 - 4 show a patient description and the Figure/Media which appear at the top of the comprehensive list of answer options you will see with each ECG case. The answer options are grouped in the following sections: General Features and P Wave Abnormalities; Rhythms; AV Conduction; Voltage or Axis/Hypertrophy; Intraventricular Conduction; Myocardial Infarction; ST, T, U Wave Abnormalities; Clinical Disorders; and Pacemaker Function.

Read the patient description and review the Figure/Media to interpret the image, identifying any abnormalities. Select the appropriate answer option(s) that correspond to your findings.

Correct answers for some cases may include choices from several sections; within a section, it may be appropriate to select more than one option. However, a selection of answer options from all sections is not required for each case.

The goal is not to identify every normal finding, nor is this an exercise in identifying minutiae or clinically unimportant details. If you believe there is insufficient data or evidence for a feature or an abnormality, make no selection(s) in that section.



Figure/Media

GENERAL FEATURES & P WAVE ABNORMALITIES**General Features**

- Normal ECG
- Normal variant
- Incorrect electrode placement
- Artifact

P Wave Abnormalities

- Right atrial abnormality/enlargement
- Left atrial abnormality/enlargement

RHYTHMS**Atrial Rhythms**

- Sinus rhythm
- Sinus arrhythmia
- Sinus bradycardia (<60)
- Sinus tachycardia (>100)
- Sinus pause or arrest
- Sinoatrial exit block
- Atrial premature complexes
- Atrial tachycardia
- Atrial tachycardia, multifocal
- Supraventricular tachycardia
- Atrial flutter
- Atrial fibrillation

AV Junctional Rhythms

- AV junctional premature complexes
- AV junctional escape complexes
- AV junctional rhythm/tachycardia

Ventricular Rhythms

- Ventricular premature complex(es)
- Ventricular parasystole
- Ventricular tachycardia (3 or more consecutive complexes)
- Accelerated idioventricular rhythm
- Ventricular escape complexes or rhythm
- Ventricular fibrillation

ATRIOVENTRICULAR CONDUCTION

- AV block, 1°
- AV block, 2° - Mobitz type I (Wenckebach)
- AV block, 2° - Mobitz type II
- AV block, 2:1
- AV block, 3°
- Wolff-Parkinson-White pattern
- AV dissociation

VOLTAGE OR AXIS/HYPERTROPHY**Abnormal QRS Voltage or Axis**

- Low voltage, limb leads
- Low voltage, precordial leads
- Left axis deviation (> -30°)
- Right axis deviation (> +100°)
- Electrical alternans

Ventricular Hypertrophy

- Left ventricular hypertrophy
- Right ventricular hypertrophy
- Combined ventricular hypertrophy

CLINICAL DISORDERS

- Brugada syndrome
- Digitalis toxicity
- Torsades de pointes
- Hyperkalemia
- Hypokalemia
- Hypercalcemia
- Hypocalcemia
- Dextrocardia, mirror image
- Acute cor pulmonale including pulmonary embolus
- Pericardial effusion
- Acute pericarditis
- Hypertrophic cardiomyopathy
- Central nervous system disorder
- Hypothermia

INTRAVENTRICULAR CONDUCTION

- RBBB, complete
- RBBB, incomplete
- Left anterior fascicular block
- Left posterior fascicular block
- LBBB, complete
- LBBB, incomplete
- Aberrant conduction (including rate-related)
- Intraventricular conduction disturbance, nonspecific type

MYOCARDIAL INFARCTION

	Age recent, or probably acute	Age indeterminate, or probably old
Anterolateral	<input type="checkbox"/>	<input type="checkbox"/>
Anterior or anteroseptal	<input type="checkbox"/>	<input type="checkbox"/>
Lateral	<input type="checkbox"/>	<input type="checkbox"/>
Inferior	<input type="checkbox"/>	<input type="checkbox"/>
Posterior	<input type="checkbox"/>	<input type="checkbox"/>

ST, T, U WAVE ABNORMALITIES

- Normal variant, early repolarization
- Normal variant, juvenile T waves
- Nonspecific ST and/or T wave abnormalities
- ST and/or T wave abnormalities suggesting myocardial ischemia
- ST and/or T wave abnormalities suggesting myocardial injury
- ST and/or T wave abnormalities suggesting electrolyte disturbances
- ST and/or T wave abnormalities secondary to hypertrophy
- Prolonged Q-T interval
- Prominent U waves

PACEMAKER FUNCTION

- Atrial or coronary sinus pacing
- Ventricular demand pacemaker (VVI), normally functioning
- Dual-chamber pacemaker (DDD), normally functioning
- Pacemaker malfunction, not constantly capturing (atrium or ventricle)
- Pacemaker malfunction, not constantly sensing (atrium or ventricle)
- Paced morphology consistent with biventricular pacing or cardiac resynchronization therapy

CARDIOVASCULAR DISEASE CERTIFICATION EXAMINATION

ECHOCARDIOGRAMS

The Echocardiogram portion of the Imaging Studies section of the examination is designed to test your ability to interpret echocardiograms.

Pages 6 - 9 show a patient description and the Figure/Media which appear at the top of a comprehensive list of answer options with each echocardiogram case. The answer options are grouped in the following sections: Left Ventricle; Right Ventricle; Atria; Valvular Heart Disease; Cardiomyopathy and Systemic Disease; Pulmonary/Aorta; Pericardial/Pleural Diseases; and Congenital Heart Disease.

Read the patient description and review the Figure/Media to interpret the images, identifying any abnormalities. Select the appropriate answer option(s) that correspond to your findings.

Correct answers for some cases may include choices from several sections; within a section, it may be appropriate to select more than one option. However, a selection of answer options from all sections is not required for each case.

The goal is not to identify every normal finding, nor is this an exercise in identifying minutiae or clinically unimportant details. If you believe there is insufficient data or evidence for a feature or an abnormality, make no selection(s) in that section.

All modalities of transthoracic and transesophageal echocardiograms may be presented, and all views will be appropriately labeled. On occasion, off-axis or unusual views may be used to highlight a relevant pathology or finding. Vertical markings on M-mode frames represent 1-cm increments; however, precise measurements are not required.

Mid-esophageal two chamber view

FR 52Hz
17cm

2D
82%
C 42
P Off
Gen

M4

- 0

- 5

- 10

- 15

G
P R

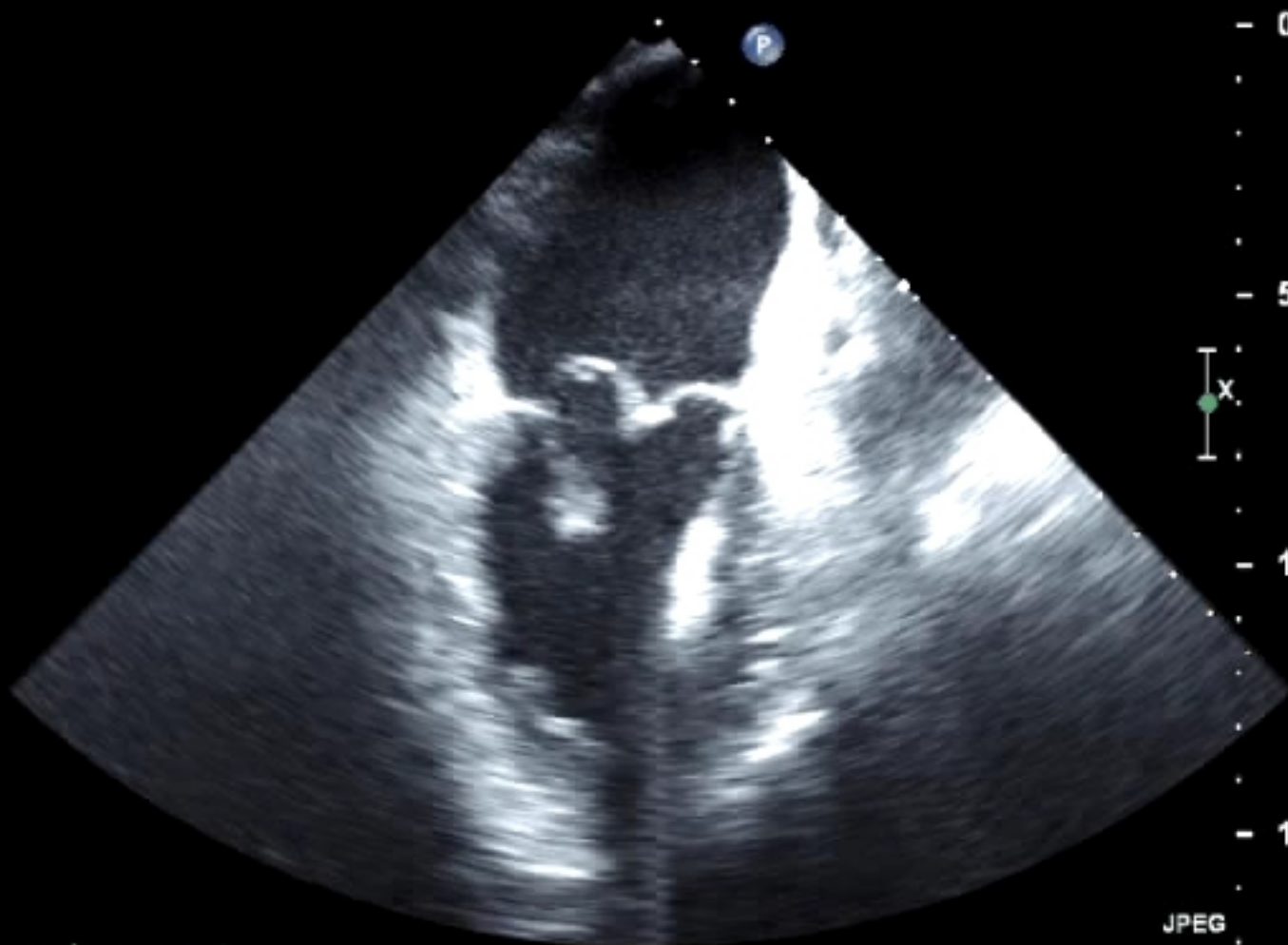
X

JPEG

123 bpm

MPEG

PAT T: 37.0C
TEE T: 39.6C



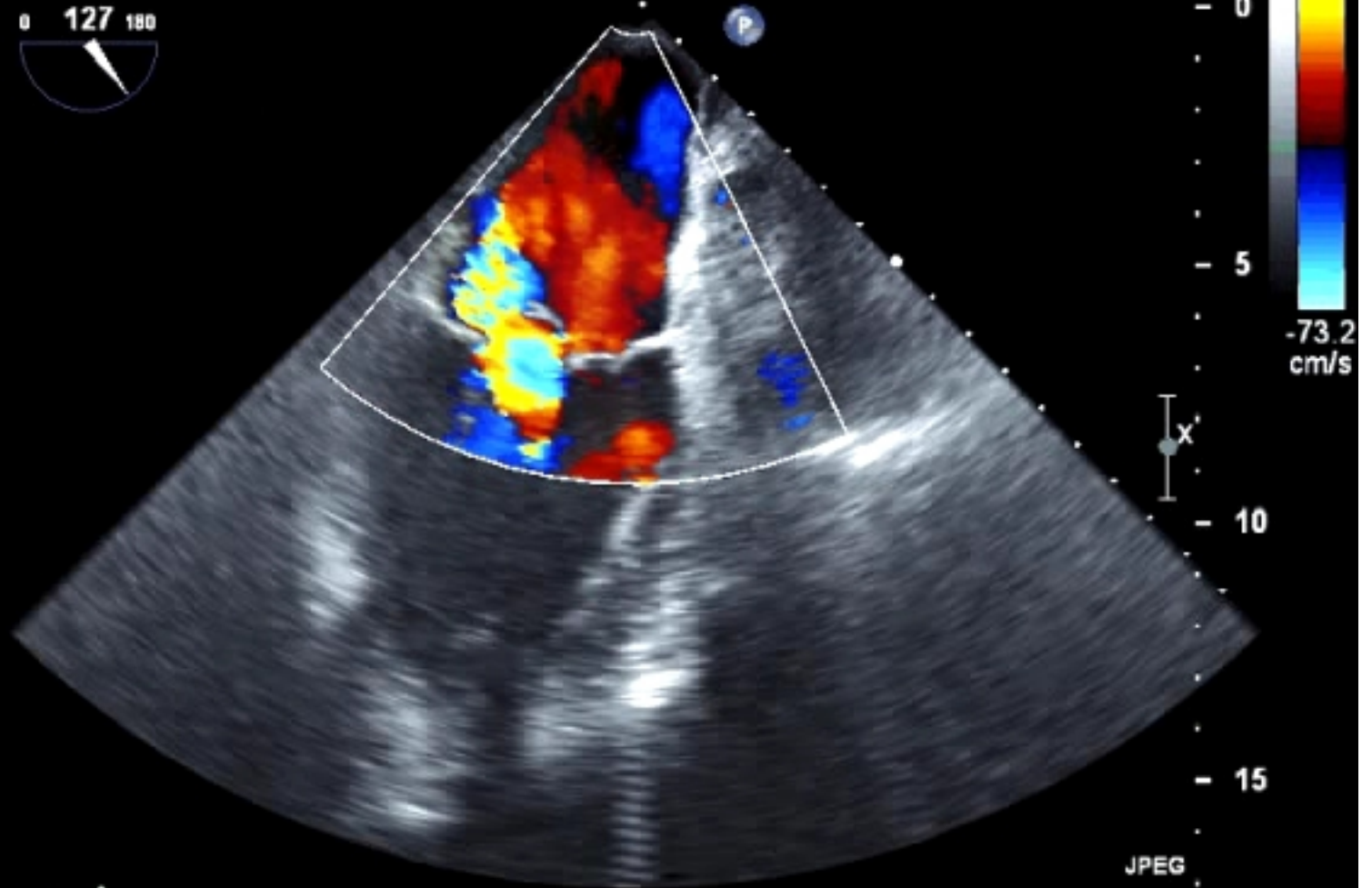
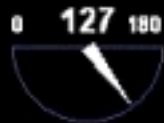Mid-esophageal two chamber view

FR 11Hz
17cm

2D
82%
C 42
P Off
Gen

CF
59%
3.3MHz
WF High
Low

G
P R



MPEG

PAT T: 37.0C
TEE T: 39.7C

JPEG

124 bpm

Transgastric short axis view

FR 52Hz
13cm

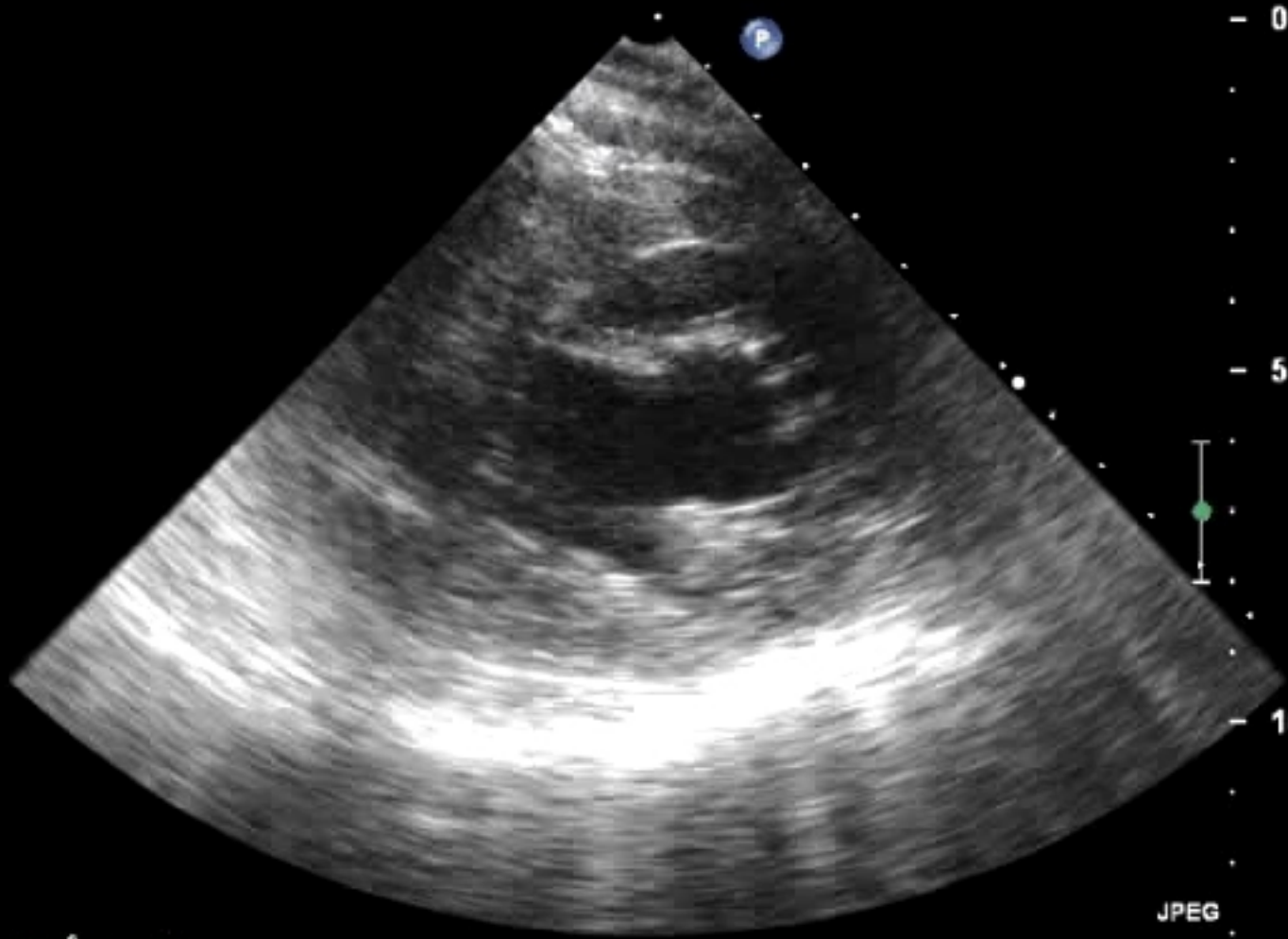
2D
79%
C 50
P Off
Gen

M4

0

5

10



MPEG

JPEG

PAT T: 37.0C
TEE T: 38.3C

124 bpm

Figure/Media

LEFT VENTRICULAR SIZE, FUNCTION, AND STRUCTURE

LV Size	LV Infarct Complications	LV Wall Thickness	LV Masses
<input type="checkbox"/> Normal	<input type="checkbox"/> Ventricular septal rupture	<input type="checkbox"/> Normal	<input type="checkbox"/> LV mass or thrombus
<input type="checkbox"/> Enlarged	<input type="checkbox"/> Free wall rupture	<input type="checkbox"/> Concentric increase	<input type="checkbox"/> Metastatic tumor
<input type="checkbox"/> Small	<input type="checkbox"/> Ruptured papillary muscle	<input type="checkbox"/> Asymmetric septal hypertrophy	

LV Diastolic Function	LV Ejection Fraction	Regional Wall Motion Abnormalities
<input type="checkbox"/> Normal	<input type="checkbox"/> Normal to hyperdynamic ($\geq 50\%$)	<input type="checkbox"/> Abnormal wall motion
<input type="checkbox"/> Grade 1 (abnormal relaxation)	<input type="checkbox"/> Mild to moderately reduced (35-49%)	<input type="checkbox"/> Global hypokinesis
<input type="checkbox"/> Grade 2 (pseudonormal)	<input type="checkbox"/> Severely reduced ($< 35\%$)	
<input type="checkbox"/> Grade 3 (restrictive)		

	Anterior	Septal	Lateral	Inferior/Posterior	Apical
Hypokinesis	<input type="checkbox"/>	<input type="checkbox"/>	<input type="checkbox"/>	<input type="checkbox"/>	<input type="checkbox"/>
Akinesis	<input type="checkbox"/>	<input type="checkbox"/>	<input type="checkbox"/>	<input type="checkbox"/>	<input type="checkbox"/>
Thinning and/or scar	<input type="checkbox"/>	<input type="checkbox"/>	<input type="checkbox"/>	<input type="checkbox"/>	<input type="checkbox"/>
Aneurysm	<input type="checkbox"/>	<input type="checkbox"/>	<input type="checkbox"/>	<input type="checkbox"/>	<input type="checkbox"/>
Pseudoaneurysm	<input type="checkbox"/>	<input type="checkbox"/>	<input type="checkbox"/>	<input type="checkbox"/>	<input type="checkbox"/>
Ischemia (with stress testing)	<input type="checkbox"/>	<input type="checkbox"/>	<input type="checkbox"/>	<input type="checkbox"/>	<input type="checkbox"/>
Viability (with stress testing)	<input type="checkbox"/>	<input type="checkbox"/>	<input type="checkbox"/>	<input type="checkbox"/>	<input type="checkbox"/>

RIGHT VENTRICULAR SIZE, FUNCTION, AND STRUCTURE

- Enlarged RV
- RV infarct
- Global hypokinesis
- RV volume overload
- RV pressure overload
- Catheter or pacemaker wire
- RV mass or thrombus

DISEASES OF THE ATRIA

- Enlarged left atrium
- Enlarged right atrium
- Atrial myxoma
- Atrial thrombus
- Metastatic tumor
- Atrial septal lipomatous hypertrophy

PERICARDIAL AND PLEURAL DISEASES

- Pericardial effusion without tamponade
- Tamponade
- Pericardial mass or hemopericardium
- Pericardial constriction
- Pericardial cyst
- Pleural effusion

TYPES OF CARDIOMYOPATHY

- Hypertrophic
- Apical hypertrophic
- Restrictive
- ARVD
- Dilated
- Noncompaction
- Takotsubo (stress induced)

CONGENITAL HEART DISEASE

- Patent foramen ovale
- Primum ASD
- Secundum ASD
- Sinus venosus ASD
- Muscular VSD
- Membranous VSD
- Supracristal VSD
- Patent ductus arteriosus
- Subaortic stenosis
- Anomalous coronary artery
- Coronary fistula
- Tetralogy of Fallot
- Ebstein's anomaly
- Complete transposition (D-TGA)
- Corrected transposition (L-TGA)

VALVULAR HEART DISEASE

Structure	Mitral Valve	Aortic Valve	Prosthetic Valve Present
<input type="checkbox"/> Calcified	<input type="checkbox"/> Calcified	<input type="checkbox"/> Calcified	<input type="checkbox"/> Normal function (includes normal gradients and closing jets)
<input type="checkbox"/> Rheumatic	<input type="checkbox"/> Rheumatic	<input type="checkbox"/> Rheumatic	<input type="checkbox"/> Pathologic regurgitation
<input type="checkbox"/> Cleft	<input type="checkbox"/> Bicuspid	<input type="checkbox"/> Bicuspid	<input type="checkbox"/> Perivalvular regurgitation
<input type="checkbox"/> Vegetation	<input type="checkbox"/> Vegetation	<input type="checkbox"/> Vegetation	<input type="checkbox"/> Elevated gradients
<input type="checkbox"/> Prolapse	<input type="checkbox"/> Flail	<input type="checkbox"/> Flail	<input type="checkbox"/> Obstruction due to thrombus or pannus
<input type="checkbox"/> Flail	<input type="checkbox"/> Fibroelastoma	<input type="checkbox"/> Fibroelastoma	<input type="checkbox"/> Dehiscence
<input type="checkbox"/> Fibroelastoma	<input type="checkbox"/> Abscess	<input type="checkbox"/> Abscess	<input type="checkbox"/> Prosthetic valve endocarditis
<input type="checkbox"/> Systolic anterior motion (SAM)			

Pulmonic Valve	Tricuspid Valve
<input type="checkbox"/> Congenitally abnormal	<input type="checkbox"/> Fails to coapt
<input type="checkbox"/> Carcinoid	<input type="checkbox"/> Carcinoid
	<input type="checkbox"/> Vegetation
	<input type="checkbox"/> Prolapse
	<input type="checkbox"/> Flail

Function	Aortic Valve Stenosis	Mitral Valve Stenosis	Tricuspid Valve Stenosis	Pulmonic Valve Stenosis	Aortic Valve Regurgitation	Mitral Valve Regurgitation	Tricuspid Valve Regurgitation	Pulmonic Valve Regurgitation
Mild/Moderate	<input type="checkbox"/>	<input type="checkbox"/>	<input type="checkbox"/>	<input type="checkbox"/>	<input type="checkbox"/>	<input type="checkbox"/>	<input type="checkbox"/>	<input type="checkbox"/>
Severe	<input type="checkbox"/>	<input type="checkbox"/>	<input type="checkbox"/>	<input type="checkbox"/>	<input type="checkbox"/>	<input type="checkbox"/>	<input type="checkbox"/>	<input type="checkbox"/>

SYSTEMIC DISEASE

- Amyloid
- Hypereosinophilia

PULMONARY DISEASE

- Findings consistent with acute pulmonary embolism
- Findings consistent with pulmonary hypertension

DISEASES OF THE AORTA

- Marfan syndrome
- Type A dissection
- Type B dissection
- Intramural hematoma
- Aortic ulcer
- Aortic enlargement or aneurysm
- Aortic rupture
- Sinus of Valsalva aneurysm
- Sinus of Valsalva rupture
- Coarctation

CARDIOVASCULAR DISEASE CERTIFICATION EXAMINATION

ANGIOGRAMS

The Angiogram portion of the Imaging Studies section of the examination is designed to test your ability to interpret coronary angiograms.

Pages 11– 14 show a patient description and the Figure/Media which appear at the top of a comprehensive list of answer options with each angiogram case. The option list is divided into five (5) columns corresponding to the coronary arteries and to bypass grafts: Left main, Left anterior descending, Left circumflex, Right, and Bypass graft. The option list also includes selections for stents (both patent and occluded).

For each diseased vessel shown in a case, you must indicate the degree of the most severe stenosis. If an intracoronary thrombus is present, include the thrombus in your assessment of the degree of stenosis. Correct answers also may include options for other findings.

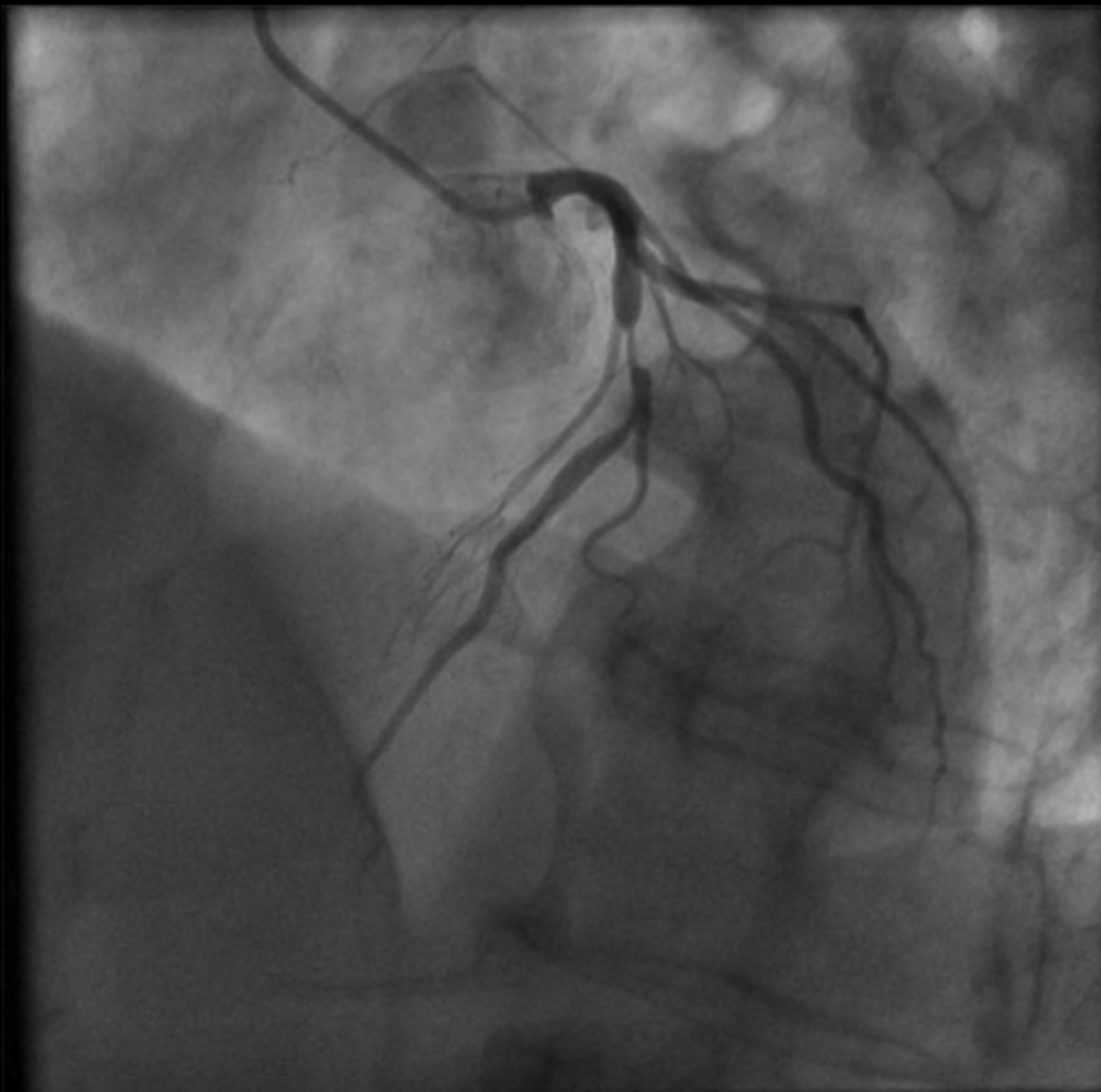
Read the patient description and review the Figure/Media to interpret the image(s), identifying any abnormalities. Select the appropriate answer option(s) that correspond to your findings.

Correct answers for some cases may include options from several columns; however, a selection of answer options from all columns is not required for each case.

NOTE: If you select the answer option labeled “Normal” for a case, select no other options.

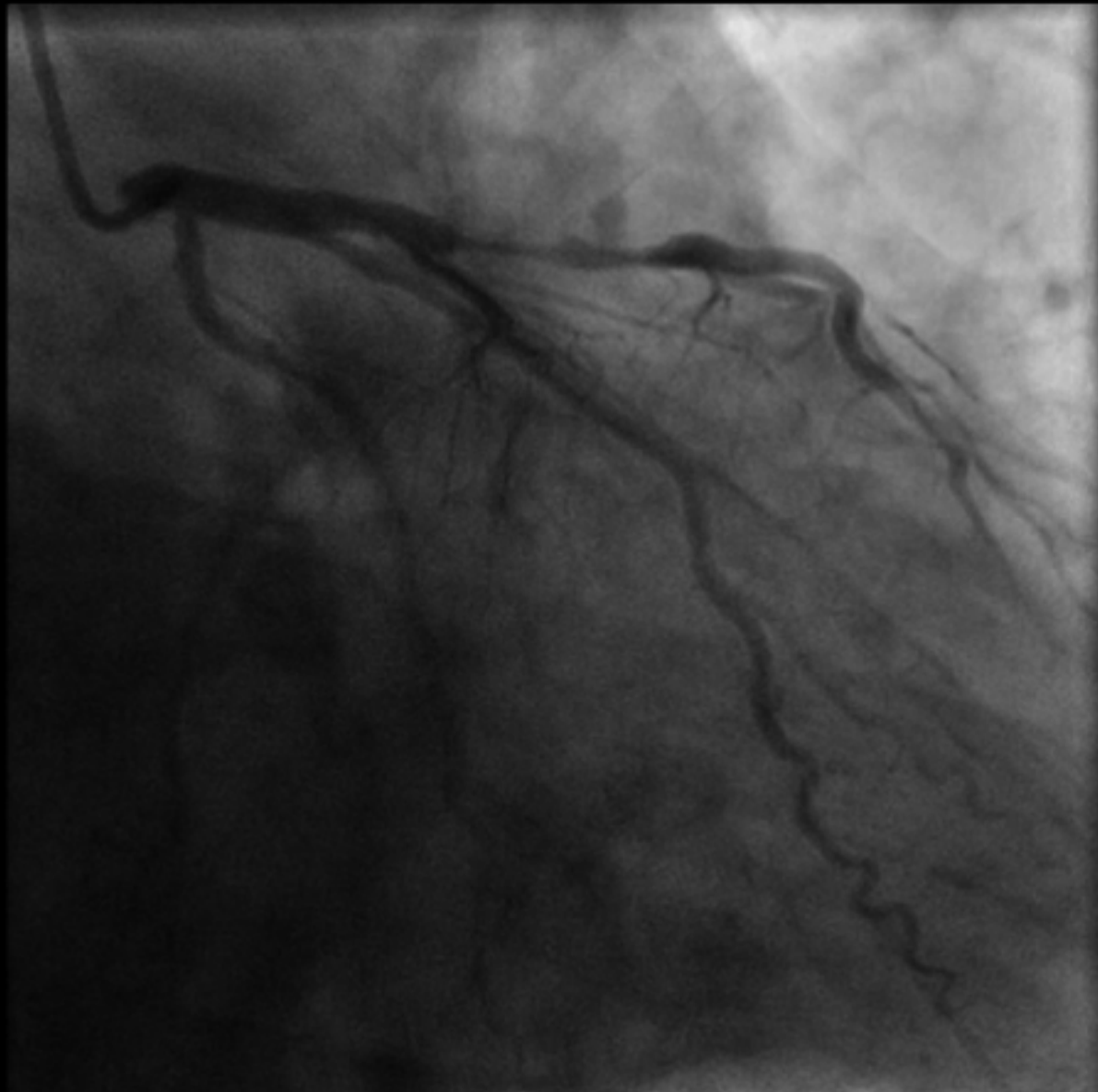
MPEG

Cranial LAO



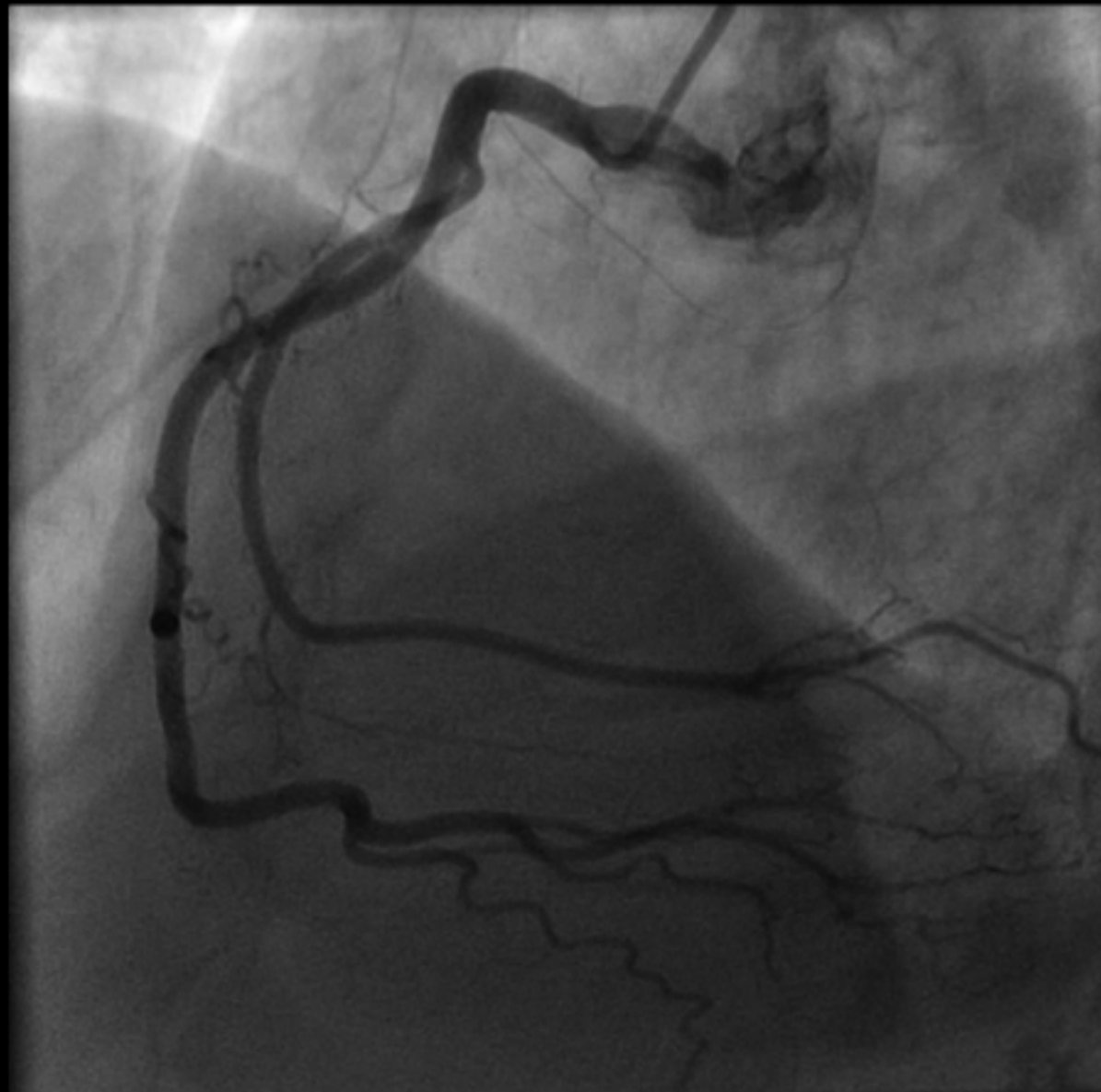MPEG

RAO



MPEG

RAO



NOTE: You must select a description for the degree of the most severe stenosis in each diseased vessel shown.

Normal

	Left main	Left anterior descending	Left circumflex	Right	Bypass graft
Fixed stenosis:					
Insignificant stenosis (<50% diameter reduction)	<input type="checkbox"/>	<input type="checkbox"/>	<input type="checkbox"/>	<input type="checkbox"/>	<input type="checkbox"/>
Moderate stenosis (50 to 75% diameter reduction)	<input type="checkbox"/>	<input type="checkbox"/>	<input type="checkbox"/>	<input type="checkbox"/>	<input type="checkbox"/>
Severe stenosis (>75% diameter reduction)	<input type="checkbox"/>	<input type="checkbox"/>	<input type="checkbox"/>	<input type="checkbox"/>	<input type="checkbox"/>
Total occlusion	<input type="checkbox"/>	<input type="checkbox"/>	<input type="checkbox"/>	<input type="checkbox"/>	<input type="checkbox"/>
Filled by collaterals		<input type="checkbox"/>	<input type="checkbox"/>	<input type="checkbox"/>	<input type="checkbox"/>
Spasm		<input type="checkbox"/>	<input type="checkbox"/>	<input type="checkbox"/>	<input type="checkbox"/>
Thrombus present		<input type="checkbox"/>	<input type="checkbox"/>	<input type="checkbox"/>	<input type="checkbox"/>
Myocardial bridge		<input type="checkbox"/>	<input type="checkbox"/>	<input type="checkbox"/>	
Anomalous origin	<input type="checkbox"/>	<input type="checkbox"/>	<input type="checkbox"/>	<input type="checkbox"/>	
Coronary fistula	<input type="checkbox"/>	<input type="checkbox"/>	<input type="checkbox"/>	<input type="checkbox"/>	
Aneurysm/Severe ectasia	<input type="checkbox"/>	<input type="checkbox"/>	<input type="checkbox"/>	<input type="checkbox"/>	<input type="checkbox"/>
Bypass graft to (indicate observed anatomical connection)		<input type="checkbox"/>	<input type="checkbox"/>	<input type="checkbox"/>	
Dissection	<input type="checkbox"/>	<input type="checkbox"/>	<input type="checkbox"/>	<input type="checkbox"/>	<input type="checkbox"/>
Stent: patent	<input type="checkbox"/>	<input type="checkbox"/>	<input type="checkbox"/>	<input type="checkbox"/>	<input type="checkbox"/>
Stent: occluded	<input type="checkbox"/>	<input type="checkbox"/>	<input type="checkbox"/>	<input type="checkbox"/>	<input type="checkbox"/>

SCORING OF SAMPLE CASES

Electrocardiogram: The correct answer for this case is Sinus rhythm (found in the Rhythms section) **AND** Wolff-Parkinson-White pattern (found in the AV Conduction section). You must select both answer choices in order to receive a correct score for this case. Selecting Lateral myocardial infarction, recent or acute, **OR** Lateral myocardial infarction, indeterminate or old, would invalidate your answer. Page 16 shows the appearance of the option list with the correct answers selected.

Echocardiogram: The correct answer for this case is ruptured papillary muscle [found in the Left Ventricle section]. Selecting mitral valve vegetation [found in the Valvular Heart Disease section] would invalidate your answer. You would receive a second point for selecting inferior/posterior hypokinesis **OR** inferior/posterior akinesis [found in the Left Ventricle section]. You would receive a third point for selecting enlarged left atrium [found in the Atria section] **AND** severe mitral valve regurgitation [found in the Valvular Heart Disease section]. Page 17 shows the appearance of the option list with the correct answers selected.

Angiogram: The correct answers for this case are insignificant stenosis of the left circumflex coronary artery **AND** insignificant stenosis of the right coronary artery **AND** severe stenosis of the left anterior descending coronary artery. You must select all three answer choices in order to receive a correct score for this case. Page 18 shows the appearance of the answer option list with the correct answers selected.

Figure/Media

GENERAL FEATURES & P WAVE ABNORMALITIES

General Features

- Normal ECG
- Normal variant
- Incorrect electrode placement
- Artifact

P Wave Abnormalities

- Right atrial abnormality/enlargement
- Left atrial abnormality/enlargement

RHYTHMS

Atrial Rhythms

- Sinus rhythm
- Sinus arrhythmia
- Sinus bradycardia (<60)
- Sinus tachycardia (>100)
- Sinus pause or arrest
- Sinoatrial exit block
- Atrial premature complexes
- Atrial tachycardia
- Atrial tachycardia, multifocal
- Supraventricular tachycardia
- Atrial flutter
- Atrial fibrillation

AV Junctional Rhythms

- AV junctional premature complexes
- AV junctional escape complexes
- AV junctional rhythm/tachycardia

Ventricular Rhythms

- Ventricular premature complex(es)
- Ventricular parasystole
- Ventricular tachycardia (3 or more consecutive complexes)
- Accelerated idioventricular rhythm
- Ventricular escape complexes or rhythm
- Ventricular fibrillation

ATRIOVENTRICULAR CONDUCTION

- AV block, 1°
- AV block, 2° - Mobitz type I (Wenckebach)
- AV block, 2° - Mobitz type II
- AV block, 2:1
- AV block, 3°
- Wolff-Parkinson-White pattern
- AV dissociation

VOLTAGE OR AXIS/HYPERTROPHY

Abnormal QRS Voltage or Axis

- Low voltage, limb leads
- Low voltage, precordial leads
- Left axis deviation (> -30°)
- Right axis deviation (> +100°)
- Electrical alternans

Ventricular Hypertrophy

- Left ventricular hypertrophy
- Right ventricular hypertrophy
- Combined ventricular hypertrophy

CLINICAL DISORDERS

- Brugada syndrome
- Digitalis toxicity
- Torsades de pointes
- Hyperkalemia
- Hypokalemia
- Hypercalcemia
- Hypocalcemia
- Dextrocardia, mirror image
- Acute cor pulmonale including pulmonary embolus
- Pericardial effusion
- Acute pericarditis
- Hypertrophic cardiomyopathy
- Central nervous system disorder
- Hypothermia

INTRAVENTRICULAR CONDUCTION

- RBBB, complete
- RBBB, incomplete
- Left anterior fascicular block
- Left posterior fascicular block
- LBBB, complete
- LBBB, incomplete
- Aberrant conduction (including rate-related)
- Intraventricular conduction disturbance, nonspecific type

MYOCARDIAL INFARCTION

	Age recent, or probably acute	Age indeterminate, or probably old
Anterolateral	<input type="checkbox"/>	<input type="checkbox"/>
Anterior or anteroseptal	<input type="checkbox"/>	<input type="checkbox"/>
Lateral	<input type="checkbox"/>	<input type="checkbox"/>
Inferior	<input type="checkbox"/>	<input type="checkbox"/>
Posterior	<input type="checkbox"/>	<input type="checkbox"/>

ST, T, U WAVE ABNORMALITIES

- Normal variant, early repolarization
- Normal variant, juvenile T waves
- Nonspecific ST and/or T wave abnormalities
- ST and/or T wave abnormalities suggesting myocardial ischemia
- ST and/or T wave abnormalities suggesting myocardial injury
- ST and/or T wave abnormalities suggesting electrolyte disturbances
- ST and/or T wave abnormalities secondary to hypertrophy
- Prolonged Q-T interval
- Prominent U waves

PACEMAKER FUNCTION

- Atrial or coronary sinus pacing
- Ventricular demand pacemaker (VVI), normally functioning
- Dual-chamber pacemaker (DDD), normally functioning
- Pacemaker malfunction, not constantly capturing (atrium or ventricle)
- Pacemaker malfunction, not constantly sensing (atrium or ventricle)
- Paced morphology consistent with biventricular pacing or cardiac resynchronization therapy

Figure/Media

LEFT VENTRICULAR SIZE, FUNCTION, AND STRUCTURE

LV Size

Normal

Enlarged

Small

LV Infarct Complications

Ventricular septal rupture

Free wall rupture

Ruptured papillary muscle

LV Wall Thickness

Normal

Concentric increase

Asymmetric septal hypertrophy

LV Masses

LV mass or thrombus

Metastatic tumor

LV Diastolic Function

Normal

Grade 1 (abnormal relaxation)

Grade 2 (pseudonormal)

Grade 3 (restrictive)

LV Ejection Fraction

Normal to hyperdynamic (>=50%)

Mild to moderately reduced (35-49%)

Severely reduced (<35%)

Regional Wall Motion Abnormalities

Abnormal wall motion

Global hypokinesis

	Anterior	Septal	Lateral	Inferior/Posterior	Apical
Hypokinesis	<input type="checkbox"/>	<input type="checkbox"/>	<input type="checkbox"/>	<input checked="" type="checkbox"/>	<input type="checkbox"/>
Akinesis	<input type="checkbox"/>	<input type="checkbox"/>	<input type="checkbox"/>	<input checked="" type="checkbox"/>	<input type="checkbox"/>
Thinning and/or scar	<input type="checkbox"/>	<input type="checkbox"/>	<input type="checkbox"/>	<input type="checkbox"/>	<input type="checkbox"/>
Aneurysm	<input type="checkbox"/>	<input type="checkbox"/>	<input type="checkbox"/>	<input type="checkbox"/>	<input type="checkbox"/>
Pseudoaneurysm	<input type="checkbox"/>	<input type="checkbox"/>	<input type="checkbox"/>	<input type="checkbox"/>	<input type="checkbox"/>
Ischemia (with stress testing)	<input type="checkbox"/>	<input type="checkbox"/>	<input type="checkbox"/>	<input type="checkbox"/>	<input type="checkbox"/>
Viability (with stress testing)	<input type="checkbox"/>	<input type="checkbox"/>	<input type="checkbox"/>	<input type="checkbox"/>	<input type="checkbox"/>

RIGHT VENTRICULAR SIZE, FUNCTION, AND STRUCTURE

- Enlarged RV
- RV infarct
- Global hypokinesis
- RV volume overload
- RV pressure overload
- Catheter or pacemaker wire
- RV mass or thrombus

DISEASES OF THE ATRIA

- Enlarged left atrium
- Enlarged right atrium
- Atrial myxoma
- Atrial thrombus
- Metastatic tumor
- Atrial septal lipomatous hypertrophy

PERICARDIAL AND PLEURAL DISEASES

- Pericardial effusion without tamponade
- Tamponade
- Pericardial mass or hemopericardium
- Pericardial constriction
- Pericardial cyst
- Pleural effusion

TYPES OF CARDIOMYOPATHY

- Hypertrophic
- Apical hypertrophic
- Restrictive
- ARVD
- Dilated
- Noncompaction
- Takotsubo (stress induced)

CONGENITAL HEART DISEASE

- Patent foramen ovale
- Primum ASD
- Secundum ASD
- Sinus venosus ASD
- Muscular VSD
- Membranous VSD
- Supracristal VSD
- Patent ductus arteriosus
- Subaortic stenosis
- Anomalous coronary artery
- Coronary fistula
- Tetralogy of Fallot
- Ebstein's anomaly
- Complete transposition (D-TGA)
- Corrected transposition (L-TGA)

VALVULAR HEART DISEASE

Structure

Mitral Valve

Calcified

Rheumatic

Cleft

Vegetation

Prolapse

Flail

Fibroelastoma

Systolic anterior motion (SAM)

Aortic Valve

Calcified

Rheumatic

Bicuspid

Vegetation

Flail

Fibroelastoma

Abscess

Prosthetic Valve Present

Normal function (includes normal gradients and closing jets)

Pathologic regurgitation

Perivalvular regurgitation

Elevated gradients

Obstruction due to thrombus or pannus

Dehiscence

Prosthetic valve endocarditis

Pulmonic Valve

Congenitally abnormal

Carcinoid

Tricuspid Valve

Fails to coapt

Carcinoid

Vegetation

Prolapse

Flail

Function

	Aortic Valve Stenosis	Mitral Valve Stenosis	Tricuspid Valve Stenosis	Pulmonic Valve Stenosis	Aortic Valve Regurgitation	Mitral Valve Regurgitation	Tricuspid Valve Regurgitation	Pulmonic Valve Regurgitation
Mild/Moderate	<input type="checkbox"/>	<input type="checkbox"/>	<input type="checkbox"/>	<input type="checkbox"/>	<input type="checkbox"/>	<input checked="" type="checkbox"/>	<input type="checkbox"/>	<input type="checkbox"/>
Severe	<input type="checkbox"/>	<input type="checkbox"/>	<input type="checkbox"/>	<input type="checkbox"/>	<input type="checkbox"/>	<input type="checkbox"/>	<input type="checkbox"/>	<input type="checkbox"/>

SYSTEMIC DISEASE

- Amyloid
- Hypereosinophilia

PULMONARY DISEASE

- Findings consistent with acute pulmonary embolism
- Findings consistent with pulmonary hypertension

DISEASES OF THE AORTA

- Marfan syndrome
- Type A dissection
- Type B dissection
- Intramural hematoma
- Aortic ulcer
- Aortic enlargement or aneurysm
- Aortic rupture
- Sinus of Valsalva aneurysm
- Sinus of Valsalva rupture
- Coarctation

NOTE: You must select a description for the degree of the most severe stenosis in each diseased vessel shown.

Normal

	Left main	Left anterior descending	Left circumflex	Right	Bypass graft
Fixed stenosis:					
Insignificant stenosis (<50% diameter reduction)	<input type="checkbox"/>	<input type="checkbox"/>	<input checked="" type="checkbox"/>	<input checked="" type="checkbox"/>	<input type="checkbox"/>
Moderate stenosis (50 to 75% diameter reduction)	<input type="checkbox"/>	<input type="checkbox"/>	<input type="checkbox"/>	<input type="checkbox"/>	<input type="checkbox"/>
Severe stenosis (>75% diameter reduction)	<input type="checkbox"/>	<input checked="" type="checkbox"/>	<input type="checkbox"/>	<input type="checkbox"/>	<input type="checkbox"/>
Total occlusion	<input type="checkbox"/>	<input type="checkbox"/>	<input type="checkbox"/>	<input type="checkbox"/>	<input type="checkbox"/>
Filled by collaterals		<input type="checkbox"/>	<input type="checkbox"/>	<input type="checkbox"/>	<input type="checkbox"/>
Spasm		<input type="checkbox"/>	<input type="checkbox"/>	<input type="checkbox"/>	<input type="checkbox"/>
Thrombus present		<input type="checkbox"/>	<input type="checkbox"/>	<input type="checkbox"/>	<input type="checkbox"/>
Myocardial bridge		<input type="checkbox"/>	<input type="checkbox"/>	<input type="checkbox"/>	
Anomalous origin	<input type="checkbox"/>	<input type="checkbox"/>	<input type="checkbox"/>	<input type="checkbox"/>	
Coronary fistula	<input type="checkbox"/>	<input type="checkbox"/>	<input type="checkbox"/>	<input type="checkbox"/>	
Aneurysm/Severe ectasia	<input type="checkbox"/>	<input type="checkbox"/>	<input type="checkbox"/>	<input type="checkbox"/>	<input type="checkbox"/>
Bypass graft to (indicate observed anatomical connection)		<input type="checkbox"/>	<input type="checkbox"/>	<input type="checkbox"/>	
Dissection	<input type="checkbox"/>	<input type="checkbox"/>	<input type="checkbox"/>	<input type="checkbox"/>	<input type="checkbox"/>
Stent: patent	<input type="checkbox"/>	<input type="checkbox"/>	<input type="checkbox"/>	<input type="checkbox"/>	<input type="checkbox"/>
Stent: occluded	<input type="checkbox"/>	<input type="checkbox"/>	<input type="checkbox"/>	<input type="checkbox"/>	<input type="checkbox"/>